

# Unscheduled bleeding with hormone replacement therapy

Fulva Gajjar Dave MBBS MD MRCOG,<sup>a,\*</sup> Tolu Adedipe MBBS MRCOG,<sup>b</sup> Stewart Disu MRCOG,<sup>c</sup>  
Raphael Laiyemo MRCOG<sup>d</sup>

<sup>a</sup>ST7 Obstetrics and Gynaecology, The Queen's Medical Centre, Nottingham NG7 2UH, UK

<sup>b</sup>ST7 Obstetrics and Gynaecology, Leeds Teaching Hospitals NHS Trust, Leeds LS1 3EX, UK

<sup>c</sup>Consultant Gynaecologist, Northwick Park Hospital, Harrow HA1 3UJ, UK

<sup>d</sup>Consultant Obstetrician and Gynaecologist, Kings Mill Hospital, Mansfield NG17 4JL, UK

\*Correspondence: Fulva Gajjar Dave. Email: [fulva.dave@nuh.nhs.uk](mailto:fulva.dave@nuh.nhs.uk)

Accepted on 16 May 2017.

## Key content

- Menopause is now considered as a mid-life event. Hormone replacement therapy (HRT) is justified when menopausal symptoms adversely affect the quality of life of the individual woman.
- Management of unscheduled bleeding with HRT remains a clinical challenge and leads to pressure on resources. The aim should be to exclude endometrial pathology and to regulate the bleeding pattern so that the woman's concerns are addressed and compliance maintained.
- The mechanisms which underlie this unscheduled bleeding are poorly understood.
- Appropriate counselling should be offered at the outset.

## Learning objectives

- To gain knowledge of the most appropriate HRT regimens used in perimenopausal, postmenopausal and hysterectomised women to minimise unscheduled bleeding.
- To learn how to tailor the treatment regimen to the individual woman's situation.

## Ethical issues

- The lack of clinical evidence for managing unscheduled bleeding should be acknowledged.
- Should clinicians initiate expensive and invasive investigations in all women with unscheduled bleeding on HRT or only select those with significant risk factors?

**Keywords:** hormone replacement therapy / menopause / unscheduled bleeding

Please cite this paper as: Dave FG, Adedipe T, Disu S, Laiyemo R. Unscheduled bleeding with hormone replacement therapy. *The Obstetrician & Gynaecologist*. 2019;21:95–101. <https://doi.org/10.1111/tog.12553>

## Introduction

Menopause is a French word introduced in 1821 by French physician CPL de Gardanne, derived from the Greek words *menus* (month) and *pause* (stop).<sup>1</sup>

Menopause is defined by the World Health Organization 1996 declaration as the permanent cessation of menstruation resulting from the loss of ovarian follicular activity. Menopause is the last menstrual bleed and can be diagnosed retrospectively after 1 year of amenorrhoea in the absence of hormonal contraception and any pathologic disorder that could be responsible for the amenorrhoea.<sup>2,3</sup>

The average age of the menopause is between 50 and 51 years.<sup>4</sup> Amudsen and Diers quoted several authors who gave an average of menopause at around 50 years, including Aristotle in the sixth century AD.<sup>5</sup> In the UK, the median age of the menopause is quoted as 51 years.<sup>6</sup>

## Pathophysiology

Follicle-stimulating hormone (FSH) is the first gonadotrophin to increase in the biological ageing process (the so-called monotrophic rise in gonadotrophins), and the last hormonal marker to decrease is estradiol, with inhibin A and inhibin B falling 2–3 years before the menopause.<sup>7</sup> The findings of plasma estradiol below 20 pg/ml (range 5–25 pg/ml) as well as an elevated FSH >50 mU/ml are consistent with cessation of ovarian function.<sup>8</sup> However, there appears to be no single or combination of hormonal marker(s) that can reliably diagnose or confirm physiological menopause, hence it is a retrospective diagnosis as defined above.<sup>2</sup>

The transitional period leading up to the menopause is characterised by irregular menstrual periods that become progressively lighter or occasionally heavier, with an increasing interval between periods and vasomotor symptoms. This is known as the perimenopausal period.<sup>9</sup>

Postmenopausal bleeding refers to any vaginal bleeding that occurs 1 year after the menopause regardless of cause but excluding expected bleeding that occurs with sequential hormone replacement therapy (HRT).

The perimenopausal and postmenopausal period is usually associated with psychological, vasomotor and urogenital symptoms, and complaints that can impact on the quality of life of the individual. Symptoms include vasomotor symptoms typified by hot flushes, night sweats, headaches and palpitations. Psychological symptoms include mood swings, irritability, nervousness, dysphoria and decreased libido, depression, loss of cognitive function and insomnia. Urogenital symptoms caused by urogenital atrophy include a burning or itching discomfort in the vagina, painful sexual intercourse and urinary tract infections. These symptoms can have a negative impact on a woman's wellbeing after the menopause.

There is interplay between vasomotor, psychological and physical symptoms associated with the perimenopausal and postmenopausal period. Hot flushes can lead to insomnia, which can result in irritability, mood swings, depression and cognitive and anxiety disorders in women, while urogenital atrophy can cause dyspareunia. The use of HRT reduces vasomotor symptoms that can be very distressing psychologically. Removing vasomotor symptoms enables patients to sleep better, thereby improving their mood and wellbeing, leading to a reduction in anxiety, depression and cognitive disorders, the so-called 'domino effect' of HRT.<sup>10</sup>

Hot flushes occur in about 70–80% of women who go through physiological menopause, although this decreases with years since menopause, with only about 25–30% of women complaining of hot flushes by 5 years after their last period.<sup>11</sup>

Progressive loss of bone mass occurs after the attainment of peak bone mass at age 25 years. This loss accelerates markedly after the menopause, predisposing women to type 1 osteoporosis, which involves mainly the trabecular bone, unlike type 2 osteoporosis, which affects both sexes and affects both trabecular and cortical bone independent of menopause.<sup>9</sup> Postmenopausal osteoporosis affects one in three women after menopause and is responsible for fractures in half of postmenopausal women.<sup>12,13</sup>

HRT has been used in the prevention and treatment of osteoporosis in postmenopausal women and has been given a grade A recommendation for anti-fracture efficacy at the spine and grade B recommendation at the hip by the Royal College of Physicians.<sup>14</sup>

HRT is used as first-line treatment for the prevention or treatment of osteoporosis in menopausal women under the age of 50 years, in women with premature menopause, after bilateral oophorectomy before the age of 45 years and in postmenopausal women with an increased risk of osteoporosis or osteoporotic fracture who are unable to tolerate other treatment such as bisphosphonates.<sup>2,14</sup>

## Hormone replacement therapy

HRT is prescribed either as an estrogen-only preparation in women who have undergone hysterectomy or as an estrogen–progestogen combination for women with a uterus to prevent endometrial hyperplasia and cancer. It can be given as a sequential combined treatment or continuous combined treatment in an attempt to relieve vasomotor symptoms, urogenital symptoms and other symptoms associated with the perimenopausal period and/or the menopause.

HRT is usually prescribed after a thorough personal history has been taken, which ensures there are no major risk factors for venous thromboembolism (VTE), stroke, coronary heart disease (CHD) and breast cancer present in the individual. There are few absolute contraindications: undiagnosed vaginal bleeding, hepatic disorders and acute vascular thrombosis. The National Institute for Health and Care Excellence (NICE) recommends that medical disorders should be optimally managed before HRT is started.<sup>2</sup> HRT can be offered as an oral, transdermal, subcutaneous, vaginal or intrauterine preparation.

HRT is justified when menopausal symptoms adversely affect the individual's quality of life. Since the NICE guidance published the advice that the lowest effective dose should be used for the shortest possible time,<sup>2</sup> many experts now agree that provided treatment is appraised annually, HRT may be continued as long as the woman perceives benefit.

Monthly combined sequential HRT involves continuous estrogen and cyclical progestogen or progesterone for 12–14 days in a 28-day cycle. It should produce regular and acceptable bleeding after the end of the progestogen phase. Continuous combined HRT involves continuous (daily) use of estrogen and a progestogen or progesterone rather than cyclical use. It should induce amenorrhoea usually within 6 months of therapy. It should only be prescribed in postmenopausal women. In women without a uterus, estrogen-only therapy is used. Continuous combined HRT can be prescribed if there is a history of severe endometriosis or occasionally after subtotal hysterectomy after careful consideration by the clinician.<sup>15</sup>

## Unscheduled bleeding with HRT

HRT used either as continuous combined or combined sequential therapy can lead to unscheduled vaginal bleeding or spotting, which is unexpected or unscheduled. This abnormal bleeding is inconvenient, leads to invasive and sometimes expensive tests to exclude intrauterine pathology and has negative effects on patient acceptability and continuity due to clinical concerns.

For women on sequential HRT, abnormal bleeding may be heavy, profuse or manifest as a change in pattern at the end

of or after the progestogen phase, or may occur at any time, when it is referred to as breakthrough bleeding.

Continuous combined regimens usually lead to amenorrhoea and therefore should not cause cyclical or breakthrough bleeding. With combined HRT, up to 80% of women will experience unscheduled bleeding or spotting in the first 6 months of treatment.<sup>16</sup> Bleeding on continuous combined HRT regimens should therefore be evaluated if it occurs after 6 months of therapy or if it occurs after amenorrhoea has been established.<sup>17</sup>

### Prevalence of unscheduled bleeding

In the combined continuous regimen, either via oral or transdermal routes, irregular bleeding is expected to occur in 0–77% of women in the first few months of treatment.<sup>18–21</sup> Later on, it decreases after 6–12 months of use, and after 9 months, only 3–10% of women will still experience it. With regard to the transdermal route, irregular bleeding or spotting occurs in 10–20% of women after 12 months of use.<sup>21</sup> In the sequential regimen, irregular bleeding is experienced by 8–40% of users.<sup>15</sup> More than half of users of this regimen may bleed before day 11 of the progestogen sequence, and less than 10% of women may experience recurrent episodes of breakthrough bleeding.<sup>15</sup> Due to unscheduled bleeding on HRT, 25–50% of women discontinue HRT.<sup>22</sup> In the Million Women study,<sup>23</sup> unscheduled bleeding appeared to be more prevalent in white women, although this may be the result of study participant bias.

### Aetiology

The mechanisms underlying unscheduled bleeding with HRT are poorly understood, and different theories have been put forward for its aetiology. The presence of pathology may lead to irregular bleeding, including atrophic vaginitis, uterine polyps, fibromas, ovarian cysts or cancer, endometrial hyperplasia or cancer, and de novo endometrial cancers.<sup>24,25</sup>

Other causes of unscheduled bleeding on HRT include: poor compliance or non-compliance with treatment; drug interactions, for example in women on liver enzyme-inducing drugs such as antiepileptic medication; gastrointestinal symptoms or pathology including a prolonged episode of diarrhoea, undiagnosed or mild Crohn's disease, or malabsorption syndrome, which can affect the bioavailability and pharmacokinetics of these medications in the circulation; and higher endogenous oestrogen production in women with obesity.<sup>21</sup>

This reinforces the importance of taking a good medical history for women being investigated for unscheduled bleeding on HRT. In the absence of any pathology, theories suggesting changes in the size of endometrial vessels and stromal expression of factors such as vascular endothelial

growth factors, which are known to regulate vascular growth and integrity, have been described.<sup>26,27</sup>

### Investigation

Investigation and management of unscheduled bleeding depends on what assessment and treatment options are available in the clinical setting. A full detailed history including a drug history and a clinical examination needs to be taken to identify any other mitigating or prevailing medical or surgical conditions. Menstrual diaries should be used to assess bleeding episodes and pattern. It is best to ascertain that the woman is postmenopausal and not perimenopausal, which would account for her irregular bleeding. In the absence of any pathology or pathologies from other organs or systems, the focus may then be limited to the urogenital area. Depending on the woman's age and sexual history, pregnancy and sexually transmitted infections should be excluded, and compliance with medication should be checked.

The most important reason to investigate abnormal uterine bleeding on HRT is to exclude endometrial malignancies or premalignant conditions like complex hyperplasia. It is also important to diagnose any other benign endometrial disease such as polyps or fibroids that could be responsible for the unexpected bleeding.

Overall, the incidence of benign pathology may be significant, yet the likelihood of malignancy is low in the majority of women on HRT.<sup>15</sup>

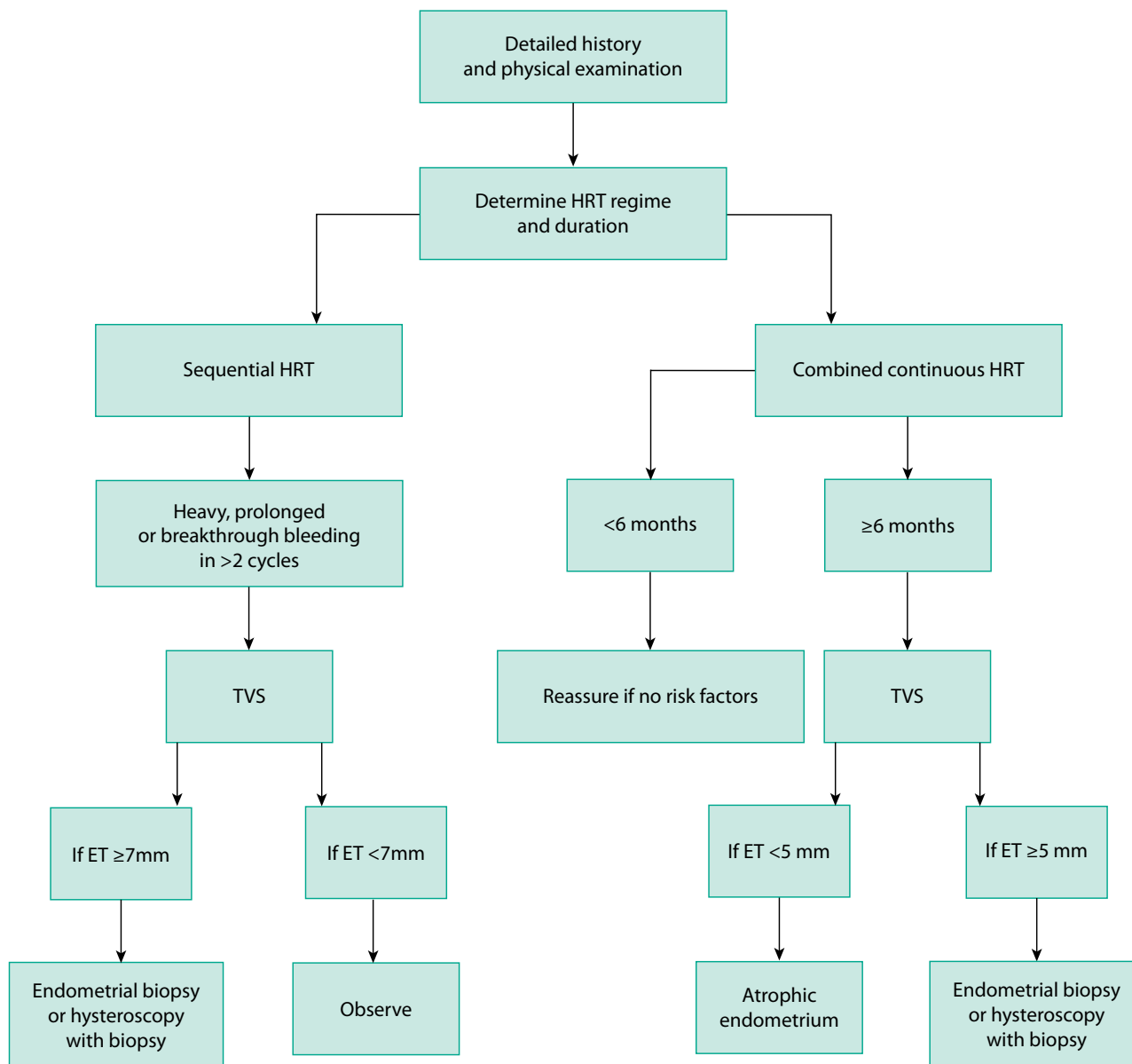
Figure 1 depicts the initial assessment plan based on the type and duration of HRT.

### Hysteroscopy

Hysteroscopy with endometrial sampling remains the gold standard for uterine cavity evaluation in the UK.<sup>28</sup> However, hysteroscopy is invasive, expensive and can lead to postoperative morbidity such as infection or postoperative pain. In addition, intraoperative complications can occur, including uterine perforation with attendant risk of injury to abdomino-pelvic structures, and may also facilitate spreading of malignant cells into the peritoneal cavity, which may lead to potential risk of iatrogenic dissemination of malignant cells that might otherwise be localised to the endometrium.

### Transvaginal ultrasound

Several studies have demonstrated that using transvaginal ultrasound as an initial tool in the investigation and evaluation of women with postmenopausal bleeding and not on HRT is safe and cost effective without compromising efficacy.<sup>29,30</sup> The technique is rapid, highly effective, relatively painless and less invasive than hysteroscopy. The efficacy and safety of transvaginal ultrasound in discriminating between women at high and low risk of



**Figure 1.** Initial assessment plan for unscheduled bleeding on HRT

If uterine pathology identified on TVS, refer for relevant treatment. Any bleeding restarts after amenorrhoea has been established – needs to be investigated.

Key: HRT = hormone replacement therapy; ET = endometrial thickness; TVS = transvaginal ultrasound

endometrial cancer is not affected by HRT use. Transvaginal ultrasound allows the simultaneous evaluation of the pelvis and lower abdominal region, and this can lead to detection of other pathologies that may have gone undetected such as a complex ovarian cyst.

Among women with postmenopausal bleeding, a thin endometrium (<5 mm) safely excludes endometrial pathology and may not require any further investigation unless recurrent/persistent bleeding or any high-risk factors are present.<sup>15,31,32</sup>

Following a negative scan showing an endometrial thickness <5 mm, the risk of endometrial cancer in postmenopausal women decreases by 90%, regardless of hormone use. Thus a woman with postmenopausal bleeding and who is not on HRT who has a pre-test probability of 10% for endometrial cancer will have a post-test probability of 1% after a negative transvaginal ultrasound.<sup>33</sup>

In women using combined sequential therapy, the false-positive rate might be decreased by measuring the endometrial thickness within a week of taking the last progestogen pill.

The sensitivity of transvaginal ultrasound does not vary significantly with hormone use, and it is accurate in excluding endometrial disease regardless of hormone use.

Endometrial thickness did not differ in women on sequential or continuous combined HRT (3.6 mm versus 3.2 mm) if measured at about the fifth day after taking the last progestogen pill.<sup>32</sup>

In women on sequential HRT with postmenopausal bleeding, the mean endometrial thickness is greater than in those women with postmenopausal bleeding who are not on sequential HRT.<sup>15</sup>

### Pipelle endometrial sampling

Histology provides definitive diagnosis in postmenopausal bleeding. Pipelle endometrial sampling or biopsy performed alone can be used in the investigation of unscheduled bleeding on HRT, as it can be done as an outpatient procedure with minimal discomfort to most women.<sup>34</sup>

Pipelle sampling becomes extremely useful where resources and access to transvaginal ultrasound or hysteroscopy is limited. However, its use alone in detecting or ruling out endometrial cancer and other pathologies is debatable. Moreover, endometrial biopsy can miss up to 20% of focal lesions like endometrial polyps.<sup>34</sup>

A meta-analysis of 39 studies including 7914 women with postmenopausal bleeding found that the endometrial detection rate of Pipelle endometrial sampling was as high as 99.6%, implying it can also be used as first-line investigation.<sup>35</sup>

There is not enough evidence to recommend when re-investigation should be done in cases of recurrent postmenopausal bleeding. Investigations after 6 months have been suggested but individualised approaches based on the risk status need to be considered.<sup>15</sup>

### Further imaging

Further imaging such as computed tomography or magnetic resonance imaging may be needed in the event of the presence of adnexal pathologies or a suspected primary malignancy elsewhere in the body.

Boxes 1 and 2 outline the criteria for ultrasound and hysteroscopic evaluation.

#### Box 1. Referral criteria for ultrasound to check endometrial thickness

- Any bleeding after 6 months of continuous combined hormone replacement therapy even in low-risk women
- Bleeding after amenorrhoea has been established
- Any bleeding in the first 6 months if any significant risk factors present

#### Box 2. Criteria for hysteroscopy

- Multiple bleeding episodes
- Focal lesions on transvaginal ultrasound
- Endometrial thickness (ET) >5 mm on continuous combined hormone replacement therapy (HRT) and ET >7 mm on sequential combined HRT
- Incomplete visualisation of endometrial echo or fragmentation of endometrial echo on ultrasound scan
- High-risk group with risk factors for endometrial disease or cancer (e.g. raised body mass index, family history of hereditary nonpolyposis colorectal cancer)

## Management

In the absence of pathology, different treatment modalities can be offered and/or adopted. For some women with persistent bleeding on HRT despite negative investigations, stopping HRT therapy by gradually phasing it out may be appropriate once vasomotor symptoms cease to exist.

It is recommended to start women at the beginning of the menopause on sequential therapy and convert to the continuous method 1 year past the menopause, or when 54 years of age, as almost 80% of women will be postmenopausal at this age.<sup>4,36</sup>

### Sequential hormone replacement therapy

After addressing possible causes like poor compliance, drug interactions and malabsorption problems, the following strategies can be used.

If the withdrawal bleeding is heavy or prolonged, increasing the dose or changing the type of progestogen or reducing the dose of estrogen may help. If bleeding occurs early in the progestogen phase, increase the dose or change the type of progestogen. Spotting before the withdrawal bleed may be due to inadequate endometrial stromal formation, and a higher estrogen dose could be tried.<sup>15</sup> If there is irregular bleeding, change the regime or increase the progestogen dose. In the case of painful bleeding, change the type of progestogen.

### Continuous combined hormone replacement therapy

Persistent bleeding after 6 months or bleeding commencing after a period of amenorrhoea should be investigated. Bleeding patterns are better with lower estrogen dose and as women get older. After excluding endometrial pathology, increasing the dose or changing the type of progestogen may help, or by fitting a 52 mg levonorgestrel-releasing intrauterine system. If all other options do not work, then changing to sequential HRT is another option.<sup>15,21</sup>

### Intrauterine system

The intrauterine system (Mirena<sup>®</sup>, Bayer plc, Reading, UK) is used in endometrial protection in women who choose to continue with their estrogen-only preparations. It avoids the systemic effects and risks of systemic progestogen, induces

endometrial atrophy and can cause regression of pre-existing small polyps and decrease formation of new endometrial polyps, thereby reducing irregular and unscheduled bleeding episodes.

### Topical vaginal estrogen

For women with significant urogenital symptoms, vaginal estrogen preparations are a viable alternative as there are no significant risks associated with this therapy and it will improve bleeding from the lower genital tract.<sup>36</sup>

### Surgery

Endometrial ablations have been offered to women who have a poor response to other interventions. Thereafter, endometrial protection should be offered because there may be some residual endometrium, especially at the cornual regions after endometrial ablation.

#### Box 3. Principles of management

- Appropriate counselling at the outset
- On continuous combined hormone replacement therapy (HRT), bleeding in the first 6 months is usually acceptable if no other risk factors, but needs investigating if any risk factors or bleeding after amenorrhoea has been established
- Sequential HRT is the preferred option in perimenopausal women
- If on sequential combined HRT, ideally check endometrial thickness using transvaginal ultrasound within a week of the last progestogen pill
- Expert opinion in refractory cases

#### Box 4. Treatment for unscheduled bleeding on hormone replacement therapy (HRT)

##### Sequential HRT

- Prolonged or heavy withdrawal bleed: increase dose/change type of progestogen or reduce estrogen
- Bleeding occurs early in progestogen phase: increase the dose/change type of progestogen
- Spotting before withdrawal period: increase estrogen dose
- Irregular bleeding: change regimen or increase progestogen dose
- Painful bleeding: change type of progestogen

##### Continuous combined HRT

- Lower estrogen dose preparations preferable
- Increase the dose or change the type of progestogen
- Convert to sequential HRT and have a regular bleed if other options fail

##### Other options

- Stop HRT
- Switch to non-oral HRT
- Offer Mirena<sup>®</sup> (Bayer plc, Reading, UK)
- Offer surgery (endometrial ablation, resection or hysterectomy) in refractory cases

Other surgical options include hysteroscopic myomectomy and polyp resections to treat benign pathology such as submucosal fibroids and benign endometrial polyps.

Some of the principles of management and treatment options are summarised in Boxes 3 and 4.

## Conclusion

Vaginal bleeding on HRT may be scheduled or unscheduled. The underlying mechanisms for unscheduled bleeding are poorly understood. It may be benign or pathological, leading to a great degree of anxiety in women taking the medication. In a small percentage of women, this concern may be justified with the need for further investigation and treatment of pathology. However, for a great number of women, unscheduled bleeding may be without prevailing pathology, and these women do not need fast-tracked referral unless there are any high-risk factors or particular clinical concern present. For them, stopping HRT abruptly in the face of continuing vasomotor pathology may lead to increased medical consultations, depressive symptoms and a decrease in their quality of life.

Endometrial assessment is indicated if unscheduled bleeding persists after the first 6 months in continuous combined HRT.

While minimising adverse effects, finding the appropriate type and dose of the constituents of HRT for each woman requires patience and compliance from both the patient and clinician. Counselling regarding these risks and mitigating factors should be offered at the outset.

## Disclosure of interests

There are no conflicts of interest.

## Contribution to authorship

RL instigated, wrote and edited the article. FD, TA, SD researched, wrote and edited the article. All authors approved the final version.

## References

- 1 Dictionary.com. *Menopause* [<http://dictionary.reference.com/browse/menopause>].
- 2 National Institute for Health and Care Excellence. *Menopause: diagnosis and management*. London: NICE;2015[<https://www.nice.org.uk/guidance/ng23>].
- 3 World Health Organization. *Research on the Menopause in the 1990s. Report of a WHO Scientific Group. WHO Technical Report Series 866*. Geneva:WHO; 1994.
- 4 Speroff L, Fritz MA. *Clinical Gynecologic Endocrinology and Infertility*. 8th edn. Philadelphia: Lippincott; 2011.
- 5 Amusden DW, Diers CJ. The age of menopause in medieval Europe. *Hum Biol* 1973;**45**:605–12.
- 6 Sarri G, Davies M, Lumsden MA. Diagnosis and management of menopause: summary of NICE guidance. *BMJ* 2015;**351**:h5746.
- 7 Øverlie I, Mørkrid L, Andersson A-M, Skakkebaek NE, Moen MH, Holte A. Inhibin A and B as markers of menopause: a five-year prospective

- longitudinal study of hormonal changes during the menopausal transition. *Acta Obstet Gynecol Scand* 2005;**84**:281–5.
- 8 Burger HG, Hale GE, Robertson DM, Dennerstein L. A review of hormonal changes during the menopausal transition: focus on findings from the Melbourne Women's Midlife Health Project. *Hum Reprod Update* 2007;**13**:559–65.
  - 9 Campbell S, Whitehead M. Oestrogen therapy and the menopausal syndrome. *Clin Obstet Gynaecol* 1977;**4**:31–4.
  - 10 Critchley H, Gebbie A, Beral V. *Menopause and hormone replacement*. London: RCOG Press; 2004.
  - 11 Melton LJ, Chrischilles EA, Cooper C, Lane AW, Riggs BL. How many women have osteoporosis? *J Bone Miner Res* 1992;**7**:1005–10.
  - 12 Peck WA, Riggs BL, Bell NH, Wallace RB, Johnston CC, Gordon SL, et al. Research directions in osteoporosis. *Am J Med* 1988;**84**:275–82.
  - 13 Royal College of Physicians. *Osteoporosis: Clinical Guidelines for Prevention and Treatment*. London: RCP; 1999.
  - 14 Barlow DH. Menopause and HRT: the state of the art in Europe. *Maturitas* 2005;**51**:40–7.
  - 15 Lou YY, Kannappan J, Sathiyathasan S. Unscheduled bleeding on HRT – do we always need to investigate for endometrial pathology? *Int J Reprod Contracept Obstet Gynecol* 2017;**6**:4174–8.
  - 16 MacLennan AH, MacLennan A, Wenzel S, Chambers HM, Eckert K. Continuous low-dose oestrogen and progestogen hormone replacement therapy: a randomised trial. *Med J Aust* 1993;**159**:102–6.
  - 17 Ettinger B, Wang SM, Leslie RS, Patel BV, Boulware MJ, Mann ME, et al. Evolution of postmenopausal hormone therapy between 2002 and 2009. *Menopause* 2012;**19**:610–5.
  - 18 Rossouw JE, Anderson GL, Prentice RL, LaCroix AZ, Kooperberg C, Stefanick ML, et al. Risks and benefits of estrogen plus progestin in healthy postmenopausal women: principal results from the Women's Health Initiative randomized controlled trial. *JAMA* 2002;**288**:321–33.
  - 19 Archer DF. Endometrial bleeding in postmenopausal women: with and without hormone therapy. *Menopause* 2011;**18**:416–20.
  - 20 Ettinger B, Li DK, Klein R. Unexpected vaginal bleeding and associated gynecologic care in postmenopausal women using hormone replacement therapy: comparison of cycles versus continuous combined schedules. *Fertil Steril* 1998;**69**:865–9.
  - 21 de Medeiros SF, Yamamoto MMW, Barbosa JS. Abnormal bleeding during menopause hormone therapy: insights for clinical management. *Clin Med Insights Womens Health* 2013;**6**:13–24.
  - 22 Hahn RG. Compliance considerations with estrogen replacement: withdrawal bleeding and other factors. *Am J Obstet Gynecol* 1989;**161**:1854–8.
  - 23 Million Women Study Collaborators. Endometrial cancer and hormone-replacement therapy in the Million Women Study. *Lancet* 2005;**365**:1543–51.
  - 24 Al-Azzawi F, Habiba M. Regular bleeding on hormone replacement therapy: a myth? *BIOG* 1994;**101**:661–2.
  - 25 Granberg S, Ylostalo P, Wikland M, Karlsson B. Endometrial sonographic and histologic findings in women with and without hormonal replacement therapy suffering from postmenopausal bleeding. *Maturitas* 1997;**27**:35–40.
  - 26 Archer DF. The effect of the duration of progestin use on the occurrence of endometrial cancer in postmenopausal women. *Menopause* 2001;**8**:245–51.
  - 27 Lau TM, Affandi B, Rogers PA. The effects of levonorgestrel implants on vascular endothelial growth factor expression in the endometrium. *Mol Hum Reprod* 1999;**5**:57–63.
  - 28 Hickey M, Doherty DA, Fraser IS, Sloboda DM, Salamonsen LA. Why does menopausal hormone therapy lead to irregular uterine bleeding? Changes to endometrial blood vessels. *Hum Reprod* 2008;**23**:912–8.
  - 29 Alfhaily F, Ewies AA. The first-line investigation of postmenopausal bleeding: transvaginal ultrasound scanning and endometrial biopsy may be enough. *Int J GynecolCancer* 2009;**19**:892–5.
  - 30 Garuti G, Sambruni I, Colonnelli M, Luerti M. Accuracy of hysteroscopy in predicting histopathology of endometrium in 1500 women. *J Am Assoc Gynecol Laparosc* 2001;**8**:207–13.
  - 31 Dijkhuizen FP, Brolmann HA, Potters AE, Bongers MY, Heintz AP. The accuracy of transvaginal ultrasonography in the diagnosis of endometrial abnormalities. *Obstet Gynecol* 1996;**87**:345–9.
  - 32 Omodei U, Ferrazzia E, Ruggeri C, Palai N, Fallo L, Dordoni D, et al. Endometrial thickness and histological abnormalities in women on hormonal replacement therapy: a transvaginal ultrasound/hysteroscopic study. *Ultrasound Obstet Gynecol* 2000;**15**:317–20.
  - 33 Smith-Bindman R, Kerlikowske K, Feldstein VA, Subak L, Scheidler J, Segal M, et al. Endovaginal ultrasound to exclude endometrial cancer and other endometrial abnormalities. *JAMA* 1998;**280**:1510–7.
  - 34 Guido RS, Kanbour-Shakir A, Rulin MC, Christopherson WA. Pipelle endometrial sampling. Sensitivity in the detection of endometrial cancer. *J Reprod Med* 1995;**40**:553–5.
  - 35 Dijkhuizen FP, Mol BW, Brolmann HA, Heintz AP. The accuracy of endometrial sampling in the diagnosis of patients with endometrial carcinoma and hyperplasia: a meta-analysis. *Cancer* 2000;**89**:1765–72.
  - 36 Bakour SH, Williamson J. Latest evidence on using hormone replacement therapy in the menopause. *The Obstetrician & Gynaecologist* 2015;**17**:20–8.